



4/30

# JOURNAL OF WILDLIFE DISEASES

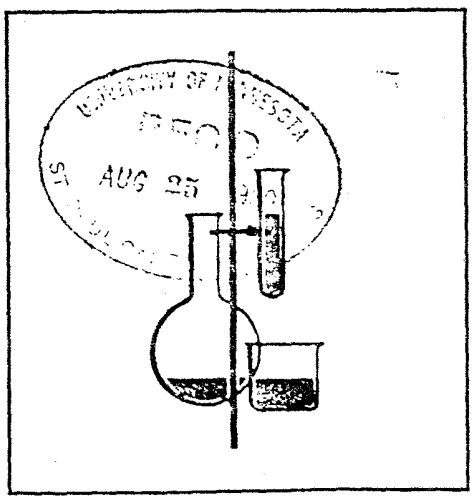
VOL. 16, NO. 3, JULY, 1980



LATEST  
ISSUE



VETERINARY LIBRARY  
ST. PAUL CAMPUS



## CLOSTRIDIAL MYONECROSIS IN A BLACK BEAR ASSOCIATED WITH DRUG ADMINISTRATION

D. M. BARNES, Department of Veterinary Pathobiology, College of Veterinary Medicine, University of Minnesota, St. Paul, Minnesota 55108, USA.

L. L. ROGERS, Wildlife Research Biologist, USDA-Forest Service, North Central Forest Experiment Station, St. Paul, Minnesota 55108, USA.

**Abstract:** Clostridial myonecrosis is described for the first time in a black bear (*Ursus americanus*). This fatal condition appeared within three days following immobilization with parenterally administered promazine hydrochloride and phencyclidine hydrochloride. Clostridial myonecrosis may be responsible for other unexplained deaths of animals following recovery from immobilizing drugs. Administration of prophylactic antibiotics to immobilized animals might be considered.

### CASE REPORT

A 14-year-old, 77 kg. female black bear was barrel-trapped and immobilized in northeastern Minnesota on 7 August 1975. She had been similarly trapped and immobilized 1 to 2 times annually for the previous six years and had been under surveillance through radiotelemetric tracking throughout that time. At this recent capture, she was immobilized with 75 mg of promazine hydrochloride<sup>□</sup> and 40 mg phencyclidine hydrochloride<sup>□</sup> administered into the heavy muscles of the right leg by means of a syringe on a pole. Total drug volume was 1.55 ml. The bear was tractable within 4 min. Blood was taken from the right femoral vein and found to have values typical for others at that time of the year. However, 3 days later, the bear was unexpectedly found dead 0.8 km from the release site. The animal's movements had not been monitored during the first 2 post-recovery days, but the body was in a good state of preservation, considering mid-summer temperatures; she was judged to have been dead less than 24 hr.

Necropsy revealed a massively swollen right pelvic limb. Palpation of the prox-

imal portion of this member elicited crepitation in the deep muscles as well as in the subcutis. Dissection disclosed the heavy muscle masses, posterior and medial to the right femur, to be black, emphysematous, swollen and necrotic. Lesions qualitatively similar, but less advanced, were present in the diaphragm.

Direct Gram-stained smears of the muscle lesion disclosed a dense clostridial population with oval subterminal spores. Direct fluorescent-antibody smears of spleen and necrotic muscle were positive for *Clostridium septicum*, *C. chauvoei* and *C. novyi*. Extensive aerobic cultures on a battery of appropriate mediums produced non-hemolytic coliform types only. Anaerobic cultures were not prepared.

Histologic examination of the necrotic muscle in the thigh and diaphragm revealed clear evidence of antemortem myonecrosis and myositis. Severe inflammatory edema and hemorrhage had greatly expanded and distorted the subcutis and fascia, and associated muscles were overtly necrotic. Although some post-mortem alterations were present,

□ Sparine, © Wyeth Laboratories, Philadelphia, Pennsylvania 19101, USA.

□ Sernylan, © Bio-ceutic Laboratories, Inc., St. Joseph, Missouri 64502, USA

neutrophil clusters and lacunar dissolution of myofibers were conspicuous. Incidental microscopic observations were sarcocysts in striated muscle, a septic fibrinous thrombus occluding a small vein of the diaphragm, a tiny focus of osteoid metaplasia in pulmonary tissue and numerous corpora amylacea in mammary tissue.

Ascarids (*Baylisascaris transfuga*) were found in the lumen of the small intestine and filarioid nematodes (*Dirofilaria ursi*) were found in the peritoneal cavity and periesophageal connective tissues. Both are common, generally nonpathogenic nematodes in black bears of the Lake Superior region.<sup>9</sup> No ectoparasites were found. Radiographs of the body did not reveal fractures or bullets.

## DISCUSSION

Death from clostridial infection has not been reported previously in a bear. The clostridial myonecrosis responsible for this fatality was, quite certainly, related to the administration of drug and/or to the sampling of blood. Although clostridia are rather ubiquitous and possess a great pathogenic potential, they are poor invaders, usually requiring external assistance to establish in the tissue for active progressive invasion. The precise mode by which this clostridial infection was initiated is uncertain. Foremost in requirements for this event would be the presence of clostridial spores or bacilli in deep tissue. That clostridia are often resident in healthy tissues, especially liver and spleen of certain species, is well accepted,<sup>3,5,6,11</sup> although healthy tissues of black bears probably have not been examined in this regard. It is also possible that clostridia were carried to the deep tissues by the hypodermic needles used for drug administration and/or blood sampling. Both procedures involved the right hind leg.

A second requirement for infection would be a microenvironment of

anaerobiosis. The deep tissue disruption by needle penetration and drug deposition might destroy local circulatory integrity and consequently reduce oxidation-reduction potential. Administration of drugs with a syringe on a pole inflicts less local tissue damage than does administration with projectile syringes, due to the explosive entry of the latter.<sup>8,10</sup> Drug administration with a sharp needle often results in a small, circular core of skin being carried into the subcutis ahead of the drug. This small cylinder of skin harboring its surface microflora is deposited in a microenvironment of tissue damage with its expected loss of vascular integrity.

The drug's role, if any, is difficult to evaluate. Cultures of the solutions employed were not made. One of the immobilizing drugs, promazine hydrochloride, carries the warning that intra-arterial injection could result in "Spasm of the digital vessels with resulting gangrene..." Moreover, other cases of clostridial infection have followed injection of other drugs capable of producing local ischemia and anoxia. Fatal cases of human gas gangrene have followed epinephrine injections.<sup>2,4,7,12</sup> The senior author has encountered epizootics of clostridial myonecrosis in neonatal pigs at sites where parenteral iron had been administered one to several days previously.

Isolation of several species of *Clostridium* from this lesion is not unusual. Even without a significant post mortem interval, mixed flora of clostridia and, occasionally, aerobes in an advanced massive myonecrotic lesion are common; gas gangrene syndromes are seldom monoclostridial.<sup>1</sup>

Once an active clostridial nidus is established, inexorable expansion follows: this progresses within hours into profound prostration and systemic lethal toxemia. Clostridial myonecrosis may be responsible for other unexplained deaths in animals restrained with drugs one to several days previously. Hypodermic in-

jections in wild animals produce penetrating wounds without the benefit of preliminary skin surface preparation or the assurance that large vessels are not entered or damaged. When animals are immobilized, consideration might be given to prophylactic antibiotics known to be tolerated by the species involved. In

repeated immobilizations involving individuals of those animal families especially susceptible to tetanus and/or blackleg, tetanus toxoid and/or multivalent blackleg bacterin probably would maintain excellent protection. Clostridial diseases, once initiated, are seldom reversible.

#### LITERATURE CITED

1. BARNES, D.M., M.E. BERGELAND and J.M. HIGBEE. 1975. Differential diagnosis of clostridial myonecrosis. *Can. Vet. J.* 16: 357-359.
2. BISHOP, R.F. and V. MARSHALL. 1960. The enhancement of *Clostridium welchii* infection by adrenalin-in-oil. *Med. J. Aust.* 2: 656-657.
3. COBB, L.M. and K.A. MCKAY. 1962. A bacteriologic study of the liver of the normal dog. *J. comp. Path.* 72: 92-96.
4. COOPER, E. 1946. Gas gangrene following the injection of adrenaline. *Lancet* 1: 459-461.
5. JAMIESON, S. 1949. The identification of *Clostridium oedematiens* and an experimental investigation of its role in the pathogenesis of infectious necrotic hepatitis ("black disease") in sheep. *J. Path. Bact.* 61: 389-402.
6. KERRY, J.B. 1964. A note on the occurrence of *Clostridium chauvoei* in the spleens and livers of healthy cattle. *Vet. Rec.* 76: 396-397.
7. MARSHALL, V. and S. SIMS. 1960. Gas gangrene after the injection of three cases. *Med. J. Aust.* 3: 653-656.
8. ROGERS, L.L. 1970. An analysis of succinylchloride chloride immobilization of black bears. M.S. thesis. Univ. of Minnesota. 59 pp.
9. ———. 1975. Parasites of black bears of the Lake Superior Region. *J. Wildl. Dis.* 11: 189-192.
10. ———, C.M. STOWE and A.W. ERICKSON. 1976. Succinylcholine chloride immobilization of black bears. Page 34. In: *Bears — Their Biology and Management*. M.R. Pelton, J.W. Lentfer and G.E. Folk, eds. IUCN Publ. new series no. 4. Morges, Switzerland.
11. SMITH, L.D.S. and A.H. JASMIN. 1956. The recovery of *Clostridium hemolyticum* from the spleens and livers of apparently healthy cattle. *J. Am. vet. med. Ass.* 129: 68-71.
12. TONGE, J.L. 1957. Gas gangrene following injections of adrenalin-in-oil. *Med. J. Aust.* 2: 936-938.

Received for publication 19 December 1978